

Caution:

Do not mark on the phantom with pen or leave printed materials contacted on its surface.
Ink marks on the phantom will be irremovable.

US-13

Infant Hip Sonography Training Phantom

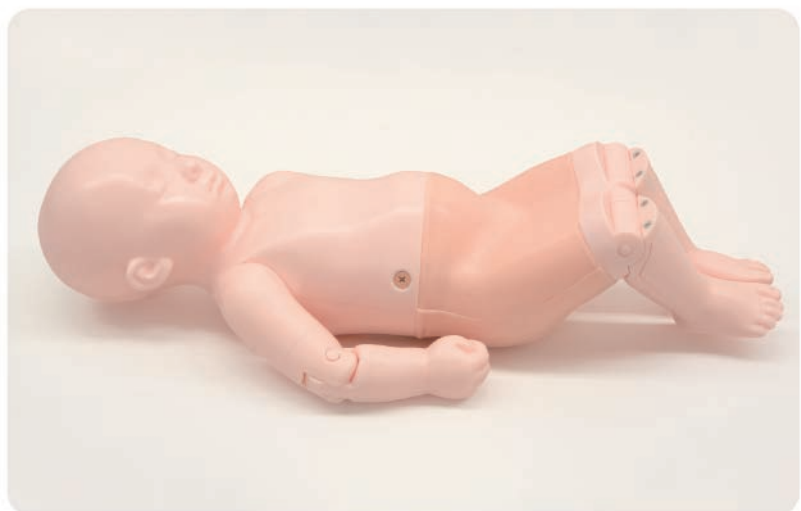Product Supervision:

Univ. Prof., Prof. hc. Reinhard Graf, M.D.

Instruction Manual

Contents

- **Please read**
 - General information P.1- P.2
- **Training procedure**
 - Before training/Training session/After training P.3
- **Training**
 - Landmarks in baby hip sonography P.4
 - Equipment and Settings P.5
 - Start Examination P.5 - P.9



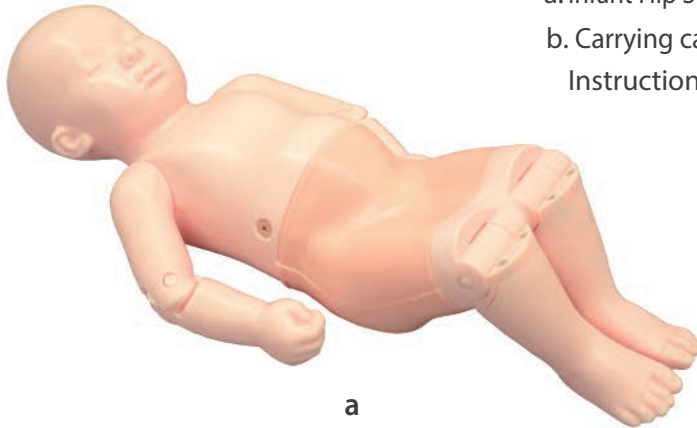
This is the world's first training phantom with ultrasound anatomy of a 6-week-old infant and it expands training opportunities for pediatricians, radiologists and orthopedists. Before working on real infants, trainees can repetitively practice on this phantom to become familiar with the examination procedures and key points. Using real ultrasound devices, trainees can learn key ultrasound landmarks to identify standard plane for Graf's classification. This is a foundation to acquire skills in handling and positioning of the baby as well as correct positioning of the transducer. The life-size full body manikin has movable arms that allows for realistic training in supporting and changing the position of the infant while interacting with his/her guardian.

● Features

1. World exclusive training model for hip sonography on a full body manikin of 6-week-old infant
2. Bilateral hips for examination
3. Key landmarks that can be recognized under ultrasound include:
 - chondro-osseous junction (bony part of femoral neck),
 - femoral head, synovial fold, joint capsule, labrum,
 - hyaline cartilage preformed acetabular roof,
 - bony part of acetabular roof, bony rim (check list I),
 - lower limb of os ilium, correct plane, labrum (check list II)
4. Facilitate anatomical understanding
5. The full body manikin with movable arms allows training in supporting and changing the position of the infant.

Set includes:

Before your first use, please ensure that you have all components listed below.



a

- a. Infant Hip Sonography Training Phantom 1
 - b. Carrying case 1
- Instruction manual (this leaflet)



b

DOs and DON'T s

DO s

Handle with care.

The materials for phantom are special composition of resin. Please handle with care at all times.

Cleaning and care

Clean the phantom completely every time after the training.

The remaining gel may deteriorate the phantom.

Keep the phantom at room temperature, away from heat, moisture and direct sunlight.

DON'T s

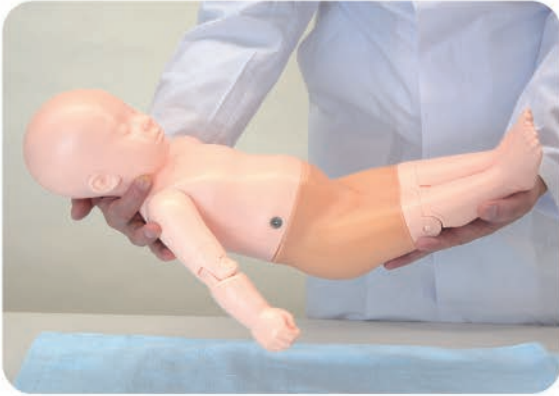
Never wipe the phantom with thinner or organic solvent.

Don't mark on the phantom with pen or leave printed materials contacted on their surface.

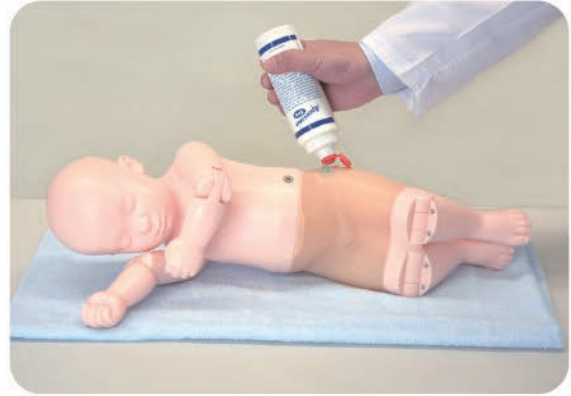Ink marks on the surface will be irremovable.

Please note: The color of the phantom may change over time, though, please be assured that this is not deterioration of the material and the ultrasonic features of the phantom stay unaffected.

1 Before training

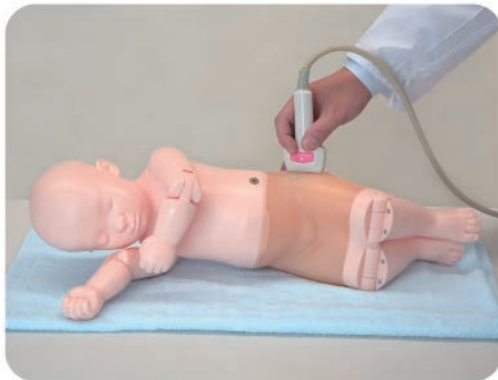

1. Knees, elbows and shoulders are movable. For your safety, always carry the phantom with two hands.

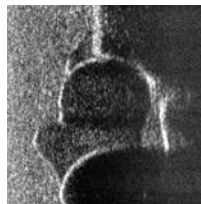

2. Spread ultrasound gel over the phantom.

2 Training session



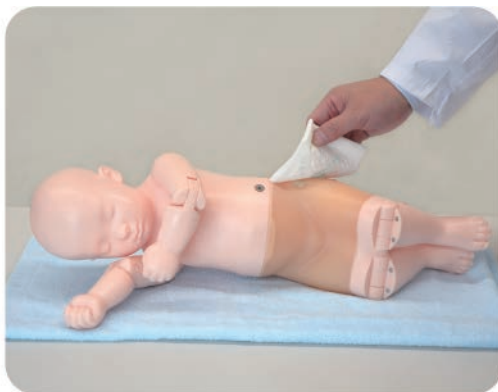The phantom can be scanned with real ultrasound devices.



Training Skills

- Setting and preparation for hip sonography
- Changing the position of the infant
- Communication and interaction with the infant's guardian
- Correct positioning and use of the transducer
- Recognition of ultrasonic landmarks for hip sonography
- Visualization of standard, anterior and posterior planes
- Interpretation and morphological classification of the sonogram

3 After training



Wipe the remaining gel completely by wet cloth.

If remaining gel gets dried up on the body, it may cause scratches and tears on the phantom material.

1 Landmarks in baby hip sonography

Learn Hip-Sonography with a Baby Phantom

Before you start:

Landmarks in baby hip sonography

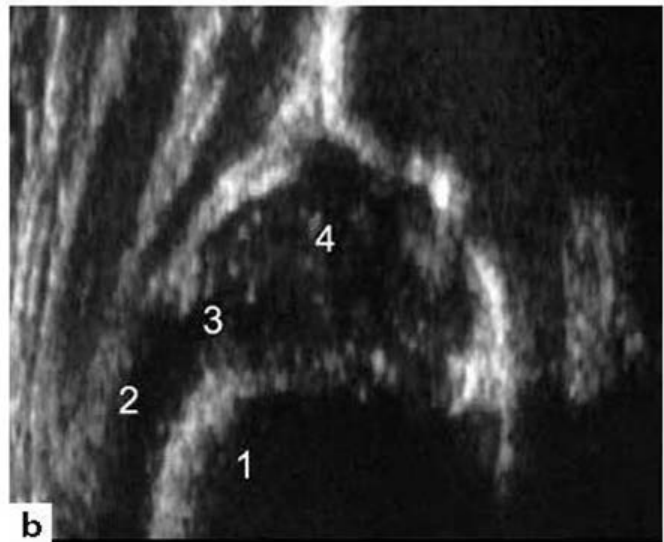
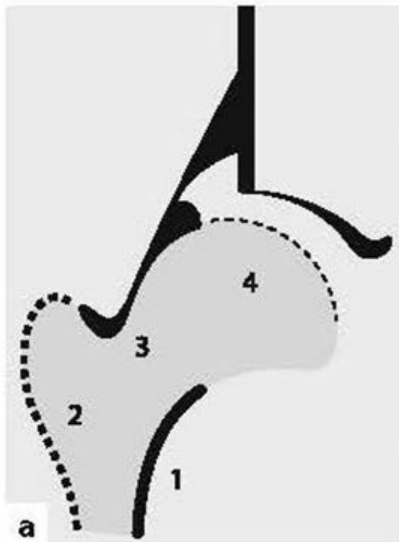
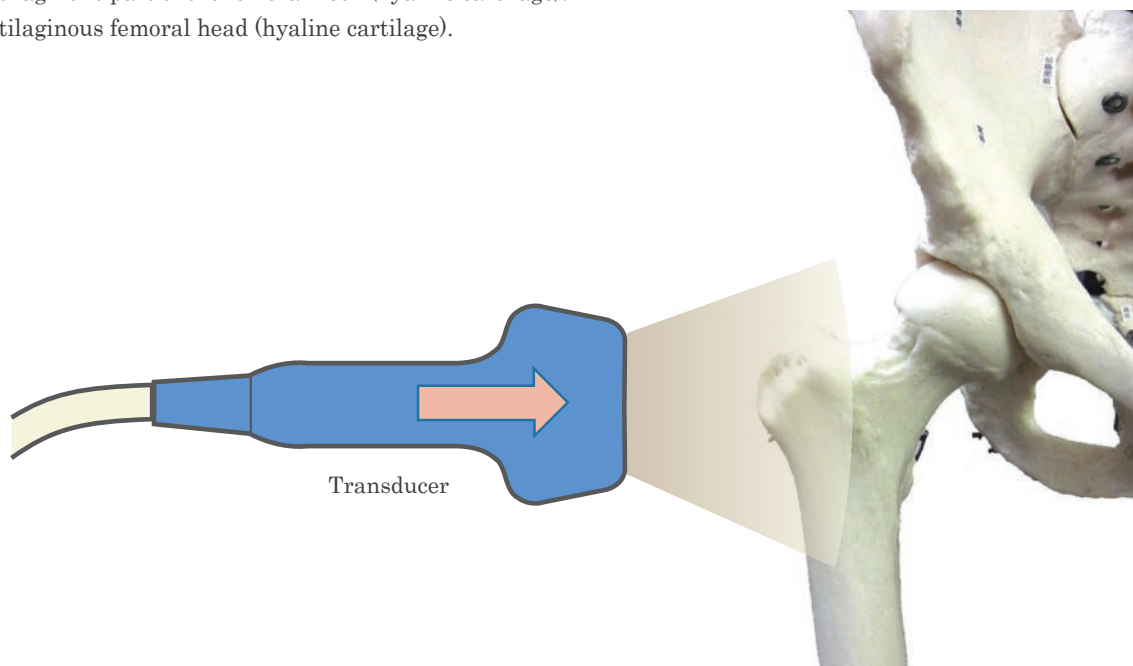


Fig.2.1a, b. Anatomical interpretation of the sonographic image of an infant proximal femur:

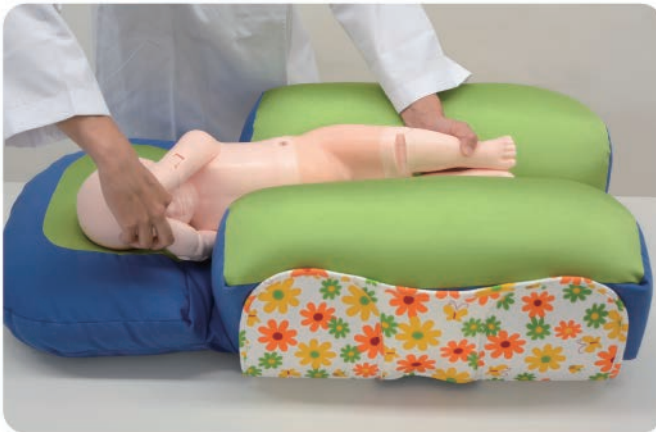1. Bony part of the femoral neck (sound shadow). The strong echo at the chondro-osseous junction separates the bony part from the cartilaginous part of the femoral neck.
2. Greater trochanter.
3. Cartilaginous part of the femoral neck (hyaline cartilage).
4. Cartilaginous femoral head (hyaline cartilage).



2 Equipment and Settings

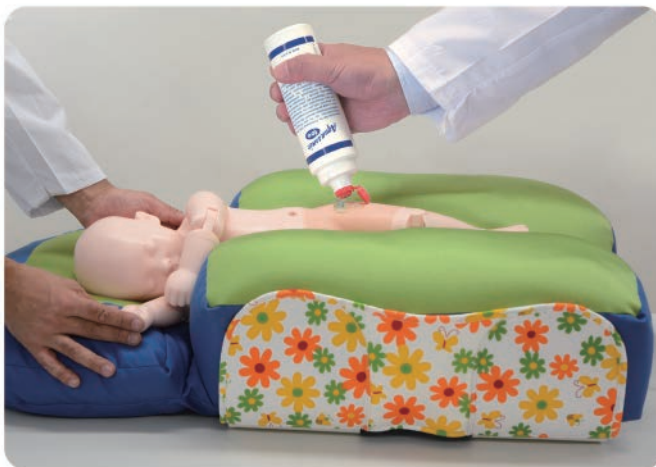- Ultrasound Scanner
 - Monitor setting: rotate 90 degrees so that surface comes to the left side of the screen
 - Dynamic Range: 50-55
 - Foot/hand switch is desirable
- Lear Transducer
 - 5Hz-7.5 Hz
- Cradle
- Ultrasound Gel

3 Start Examination



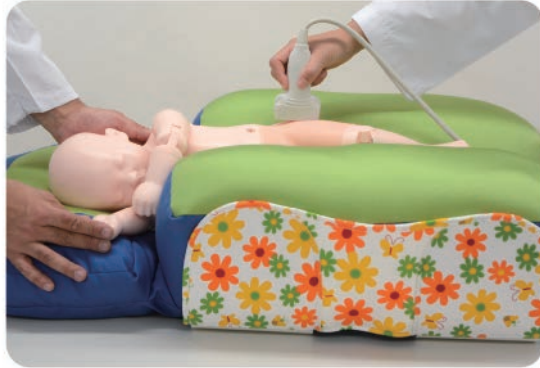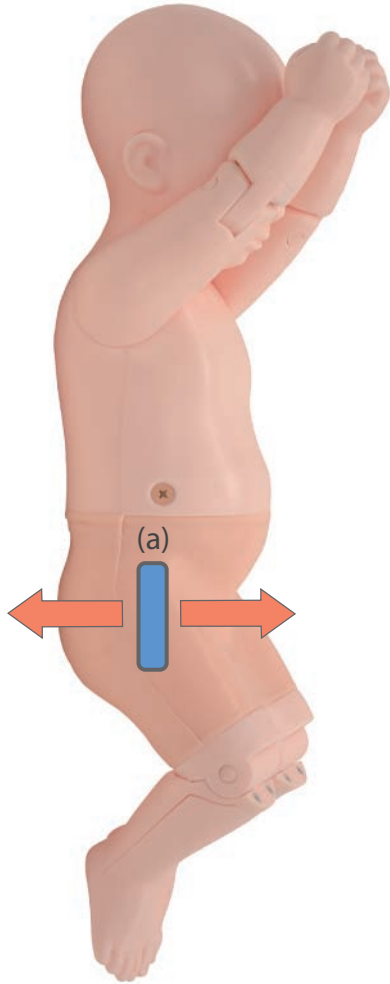
1. Position the phantom on the cradle laterally.

*Pecora: examination cushion for hip sonography not included in

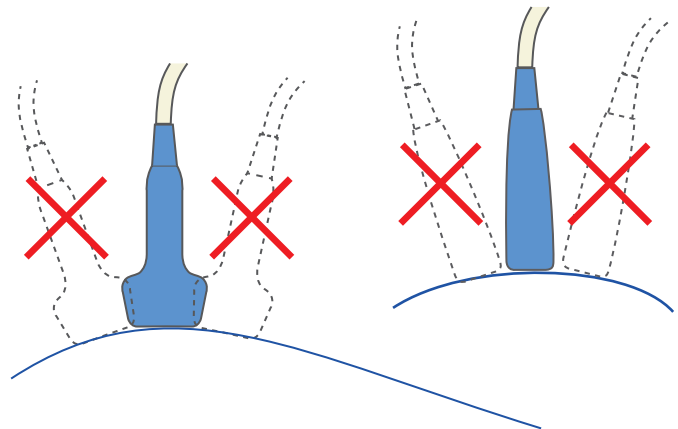


2. Spread the gel over the examination area.

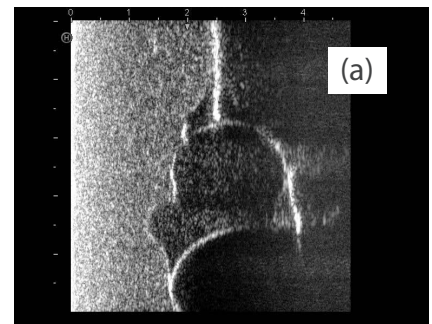
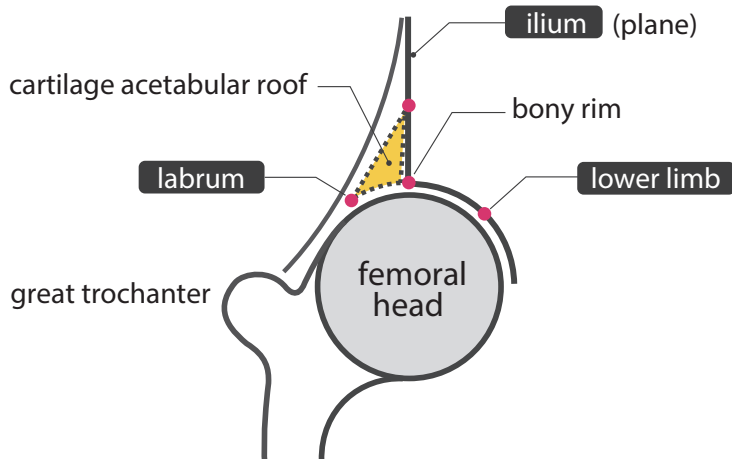
3 Start Examination



Put the transducer gently over the hip joint.
Hold the transducer
- parallel to body-axis
- perpendicularly (do not tilt)

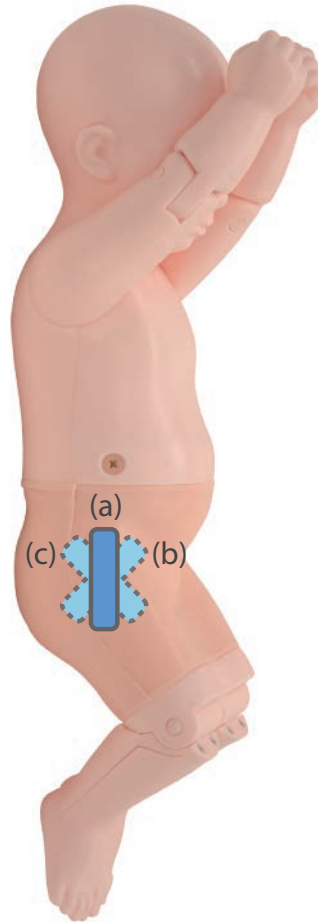


1) Find the lower limb first.



3 Start Examination

- 2) Check the plane (ilium!!!)
- 3) Rotate the transducer in the standard plane.

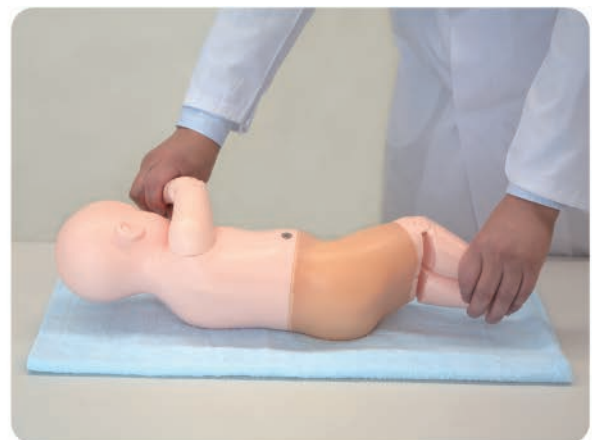
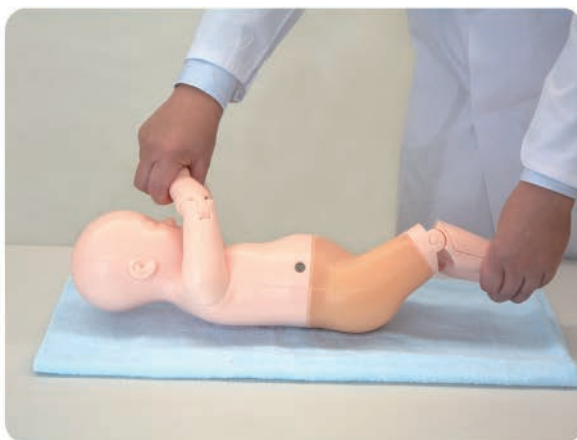
ANTERIOR PLANE
(Sonography) (b)

POSTERIOR PLANE
(Sonography) (c)

- 4) Check the lower limb again, repeat the process if necessary.

Turn the baby to right lateral by holding hands and legs.



3 Start Examination

Scan the right hip
Landmarks and Classification

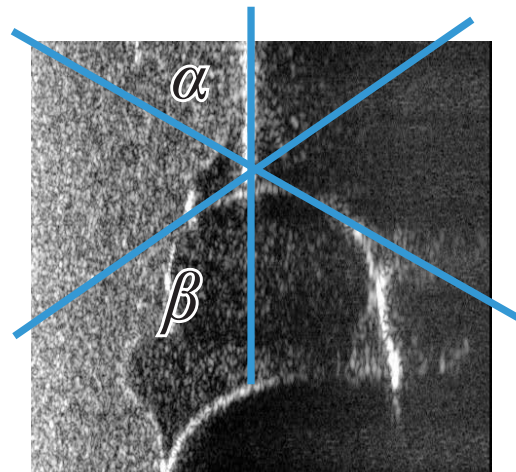
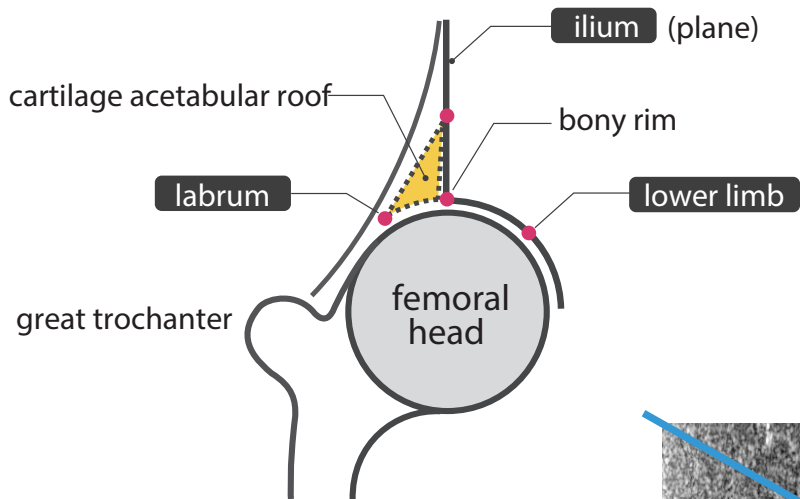


Table 6.1. Synopsis of sonographic hip types

Type according Graf	Bony roof/ bony roof angle α	Superior bony rim (bony promontory)	Cartilaginous roof/ Cartilaginous roof angle β	Age
Type I mature hip	good $\alpha \geq 60^\circ$	angle / slightly rounded ("blunt")	covers the femoral head I a $\rightarrow \beta < 55^\circ$ (extending far distance over the femoral head) I b $\rightarrow \beta < 55^\circ$ (extending short distance over the femoral head)	any age
Type II a (+) physiological immature \rightarrow appropriate for age	adequate (satisfactory) $\alpha = 50-59^\circ$ (minimal degree of maturity is attain – look at the "sonometer")	rounded	covers the femoral head	0 to 12 weeks
Type II a (-) physiological immature \rightarrow maturational deficite	deficient $\alpha = 50-59^\circ$ (minimal degree of maturity is not attain – look at the "sonometer")	rounded	covers the femoral head	> 6 to 12 weeks
Type II b delay of ossification	deficient $\alpha = 50-59^\circ$	rounded	covers the femoral head	> 12 weeks
EXEPTION: Type II coming to maturity	deficient	angular (!)	covers the femoral head. (echogenic because of ossification)	any age
Type II c (critical age) II c stable/ II c unstable	severely deficient $\alpha = 43-49^\circ$	rounded to flattened	still covers the femoral head $\beta < 77^\circ$	any age
Type D decentering hip $\rightarrow \beta > 77^\circ$	severely deficient $\alpha = 43-49^\circ$	rounded to flattened	displaced $\beta < 77^\circ$	any age
Type III a eccentric hip $\rightarrow \alpha < 43^\circ$	poor $\alpha < 43^\circ$	flattened	pressed upwards – without structural alteration (devoid of echoes) proximal perichondrium goes up to the contour of the iliac wall	any age
Type IV eccentric hip $\rightarrow \alpha < 43^\circ$	poor $\alpha < 43^\circ$	flattened	pressed Downwards (horizontal or mulded prpximal perichondrium	any age



Caution

Do not mark on the phantom with pen or leave printed materials contacted on its surface. Ink marks on the phantom will be irremovable.

The contents of this manual are subject to change without prior notice.

No part of this instruction manual may be reproduced or transmitted in any form without permission from the manufacturer. Please contact manufacturer for extra copies of this manual which may contain important updates and revisions.

Please contact manufacturer with any discrepancies, typos, or mistakes in this manual or product feedback. Your cooperation is greatly appreciated.

KYOTO KAGAKU co.,LTD

URL:<http://www.kyotokagaku.com> e-mail:rw-kyoto@kyotokagaku.co.jp

■ Main Office and Factory

15 Kitanechoya-cho Fushimi-ku Kyoto 612-8388, Japan
Telephone : 81-75-605-2510
Facsimile : 81-75-605-2519

■ KyotoKagaku America Inc.

USA,Canada,and South America
3109 Lomita Boulevard, Torrance, CA 90505 ,USA
Telephone : 1-310-325-8860
Facsimile : 1-310-325-8867